

Cyclosporine A induced arteriolopathy in a rat model of chronic cyclosporine nephropathy

BESSIE A. YOUNG, EMMANUEL A. BURDMANN, RICHARD J. JOHNSON, TAKESHI ANDOH,
WILLIAM M. BENNETT, WILLIAM G. COUSER, and CHARLES E. ALPERS

Division of Nephrology, Department of Medicine and Department of Pathology, University of Washington, Seattle, Washington, and Division of Nephrology, Hypertension and Clinical Pharmacology, Oregon Health Sciences University, Portland, Oregon, USA

Cyclosporine A induced arteriolopathy in a rat model of chronic cyclosporine nephropathy. Chronic cyclosporine (CsA) nephrotoxicity is a major complication of heart, bone marrow, and renal transplantation, and is characterized in humans by striped interstitial fibrosis, tubular dilatation and atrophy, and hyalinization of hilar arterioles. This last feature is highly specific for cyclosporine injury and has been difficult to reproduce in normotensive animal models. Salt-depletion has been shown to sensitize rodents to the effects of CsA and accelerate the disease process. We conducted sequential studies in chronically salt depleted, pair fed rats treated with CsA (15 mg/kg, s.c.) or an equivalent dose of olive oil vehicle, and found a histologic lesion associated with CsA that consisted of striped cortical interstitial fibrosis, tubular dilatation and atrophy, and hyalinization of many afferent arterioles. The arteriolopathy was first detected at day 10 with progressive hyalinization of arterioles continuing until termination of the study at day 35. The arteriolopathy consisted initially of eosinophilic granular transformation of smooth muscle cells comprising afferent hilar glomerular arterioles, and progressed to foci of smooth muscle cell vacuolization and accumulation of discrete hyaline deposits in vessel walls. Electron microscopy demonstrated marked accumulation of typical renin granules throughout the smooth muscle cell cytoplasm, corresponding to the eosinophilic granular transformation revealed histologically. Immunocytochemistry confirmed the up-regulated production of renin in these vessels. This study documents a rodent model for CsA arteriolopathy and CsA-associated interstitial fibrosis that strikingly reproduces the most characteristic nephropathic effects of cyclosporine found in human patients treated with this agent. This model offers an opportunity to test therapeutic interventions that might block or ameliorate the most serious nephrotoxic effects of this drug.

Cyclosporine (CsA) has improved organ transplantation survival markedly since its introduction by Borel et al [1], and cyclosporine-based immunosuppression has been used successfully as therapy for a number of primary renal and non-renal disease states as well. A major complication of long-term therapy is chronic CsA nephropathy, characterized by tubular vacuolization, striped cortical interstitial fibrosis, and a prominent vascular injury manifested by hyalinosis of hilar arterioles, and terminal portions of small muscular (interlobular) arteries [2]. This arteriolopathy is thought to be the most pathognomonic lesion of

chronic CsA nephropathy. This renal arteriolopathy has been documented in all solid organ transplant settings, involving the native kidneys of recipients of heart [3–6] and liver allografts [7], as well as transplanted kidneys [8–10]. It has also been documented in the kidneys of patients receiving bone marrow transplants [6], and in those of patients being treated with CsA for autoimmune diseases [11–15]. The lesion consists primarily of endothelial cell swelling, and nodular hyaline protein deposition in afferent arterioles associated with areas of smooth muscle cell (SMC) injury and necrosis [16]. However, little is known about its pathogenesis primarily due to the lack of an adequate animal model.

This lesion has been reproduced in the SHR hypertensive rat given super therapeutic doses of CsA [17], and some features of this lesion have also been observed by electron microscopy in Wistar rats given extremely high doses of CsA [18]. The arteriolopathy has also been described in rabbits receiving CsA [19]. However, a histologically distinguishable lesion resembling the CsA arteriolopathy identified in sections of human renal biopsies has not been identified to date in cyclosporine-treated normotensive rats.

Salt depletion has been shown to increase the susceptibility of rodents to the effects of CsA, and this maneuver facilitates production of interstitial fibrosis that mimics the striped interstitial fibrosis found in humans [20, 21]. In studies reported elsewhere we have provided data on interstitial cellular events as they relate to the subsequent development of fibrosis in this model [22, 23]. Here we document a model of chronic CsA nephropathy in salt depleted rats in which a prominent component is the development of an arteriolopathy that is virtually indistinguishable morphologically from the CsA arteriolopathy in humans.

Methods

Experimental design

Forty-eight adult, male Sprague-Dawley rats (Charles River, Wilmington, MA, USA), 225 to 250 g, were housed in individual cages and fed a low sodium diet (0.05% sodium, Teklad, Premier, WI, USA), with water *ad libitum*. After one week on a low salt diet, weight matched rats were randomly assigned to CsA administration of 15 mg/kg s.c. daily (Sandoz Research Inst., East Hanover, NJ, USA), or an equivalent dose of the vehicle, olive oil.

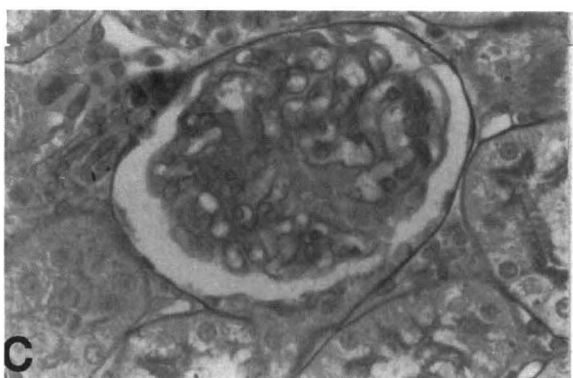
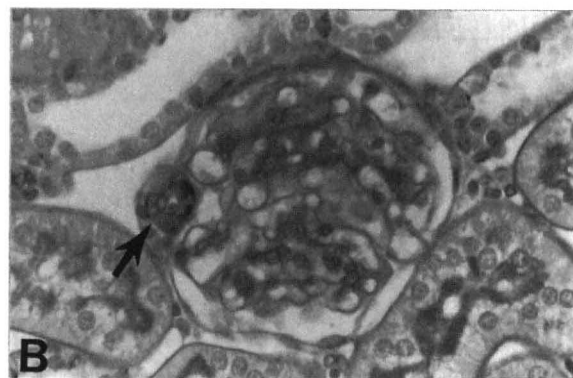
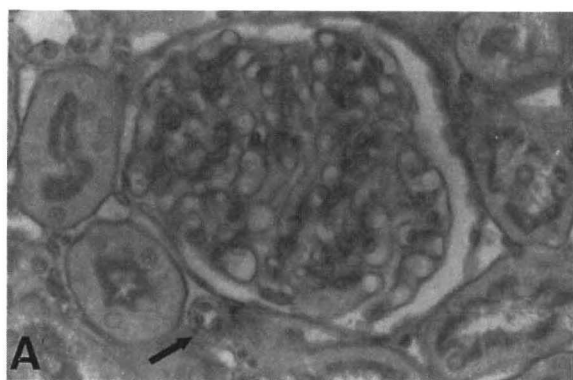


Fig. 1. A. Representative cortical structures from a control rat. Normal appearance of glomeruli, tubules, interstitium and hilar arteriole (arrow) is demonstrated. PAS stain, 365 \times . B. Day 10 cyclosporine treated animal. Smooth muscle cells of an affected hilar arteriole (arrow) are hypertrophied and show granular eosinophilic transformation compared to normal arteriole seen in 1A. PAS stain, 365 \times . C. Day 10 cyclosporine-treated animal. Cyclosporine effect on vascular smooth muscle cells is limited to the terminal arteriole. The more proximal arterial smooth muscle cells are morphologically normal. PAS stain, 365 \times .

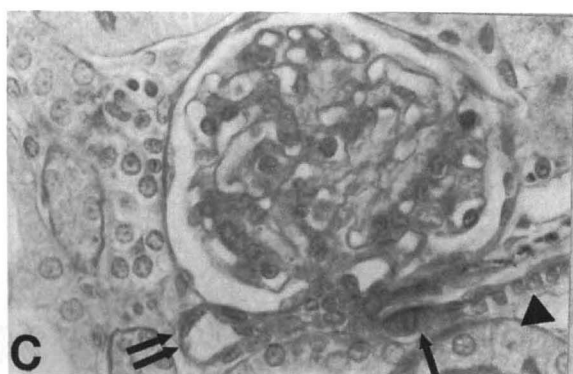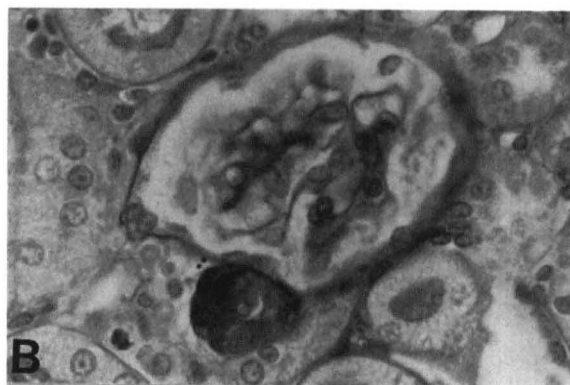
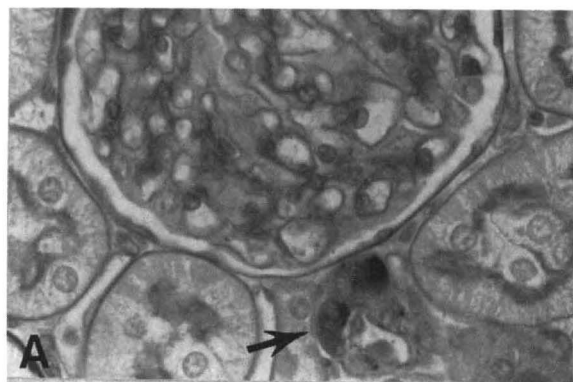


Fig. 2. A. Day 35 cyclosporine-treated animal. There is discrete eosinophilic transformation of some, but not all, smooth muscle cells comprising a hilar arteriole (arrow). Adjacent glomerulus and tubular structures are morphologically normal. PAS stain, 470 \times . B. Day 35 cyclosporine-treated animal. More uniform, circumferential injury of hilar arteriolar smooth muscle cells. PAS stain, 470 \times . C. Day 26 cyclosporine-treated animal. There is focal smooth muscle cell injury of the glomerular afferent arteriole (arrow), with sparing of contiguous terminal interlobular artery (arrowhead) and sparing of efferent arteriole (double arrow). PAS stain, 470 \times .

Rats were pair fed and control and CsA treated rats were each further divided into four groups of six rats each. Control and experimental groups were sacrificed and renal tissue was obtained at days 5, 10, 26, and 35.

Histology

Renal tissue at sacrifice was fixed in methyl Carnoy's solution, processed and embedded in paraffin, and cut into 4 μ sections using conventional techniques. Slides were stained with periodic

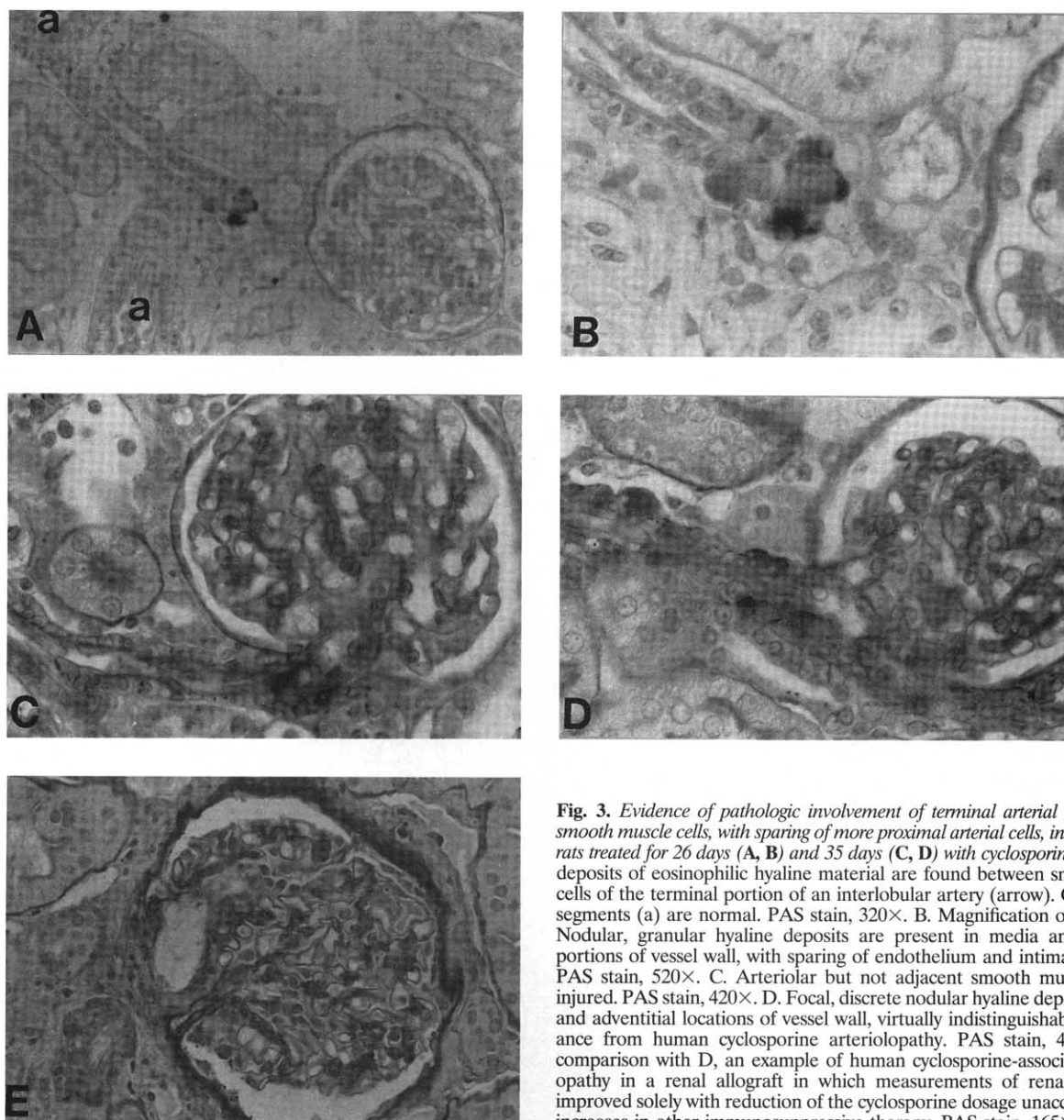


Fig. 3. Evidence of pathologic involvement of terminal arterial and arteriolar smooth muscle cells, with sparing of more proximal arterial cells, in three different rats treated for 26 days (A, B) and 35 days (C, D) with cyclosporine. A. Distinct deposits of eosinophilic hyaline material are found between smooth muscle cells of the terminal portion of an interlobular artery (arrow). Other arterial segments (a) are normal. PAS stain, 320 \times . B. Magnification of lesion in A. Nodular, granular hyaline deposits are present in media and adventitial portions of vessel wall, with sparing of endothelium and intima from injury. PAS stain, 520 \times . C. Arteriolar but not adjacent smooth muscle cells are injured. PAS stain, 420 \times . D. Focal, discrete nodular hyaline deposits in media and adventitial locations of vessel wall, virtually indistinguishable in appearance from human cyclosporine arteriolopathy. PAS stain, 420 \times . E. For comparison with D, an example of human cyclosporine-associated arteriolopathy in a renal allograft in which measurements of renal dysfunction improved solely with reduction of the cyclosporine dosage unaccompanied by increases in other immunosuppressive therapy. PAS stain, 165 \times .

acid and Schiff's reagent (PAS), with a hematoxylin counterstain. Tissue sections were assessed for morphologic changes. Immunohistochemical staining of the sections was performed utilizing a murine monoclonal antibody raised against human renin as previously described [24, 25], using standard immunoperoxidase procedures [26]. Controls included substitution of the primary antibody with a irrelevant monoclonal antibody.

Electron microscopy

Portions of the renal tissue specimens were fixed in 1/2 strength Karnovsky's solution and processed as previously described [26]. Thin sections were mounted on coated nickel grids, and stained with osmium followed by uranyl acetate. Sections were examined using a Phillips 410 electron microscope.

Results

Renal functional data for the animals reported in this investigation are given in the companion manuscript to this study [23].

Of specific note, no differences in blood pressure between cyclosporine treated and control rats were identified at any time point studied. CsA treated animals developed a recognizable and widespread afferent arteriolar hyalinosis by day 10, with the most advanced lesions observed at days 26 and 35. The hyalinization was confined to the afferent arterioles and spared contiguous more proximal portions of the arterial tree, comprising interlobular and larger arteries. In many examples, the arterial tree could be followed from the interlobular arteries to the terminal afferent arterioles of individual glomeruli. Such examples permitted the demonstration that it was the afferent arteriole and not the more proximal contiguous arterial structures, nor adjacent efferent arterioles unattached to larger arteries, that were affected by the hyalinosis lesions (Figs. 1 to 3). The normal rat glomerular hilar arteriole is composed of a thin single layer of smooth muscle cells overlying an endothelial lining (Fig. 1A). In salt depleted animals after 10 days of cyclosporine treatment, approximately 1/5 to 1/2 of all identifiable arterioles showed swelling of some or all of the

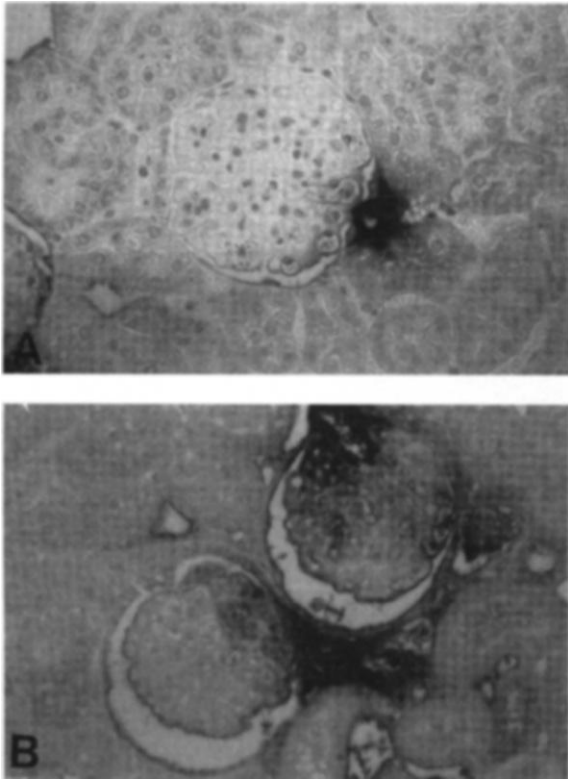


Fig. 4. A. Normal pattern of rat arteriolar and juxtaglomerular apparatus expression of renin as detected immunocytochemically. Immunoperoxidase, 300 \times . B. Day 35 cyclosporine-treated animal. There is more widespread renin expression by the hilar arterial and arteriolar vasculature as well as other components of the juxtaglomerular apparatus. Immunoperoxidase, 175 \times .

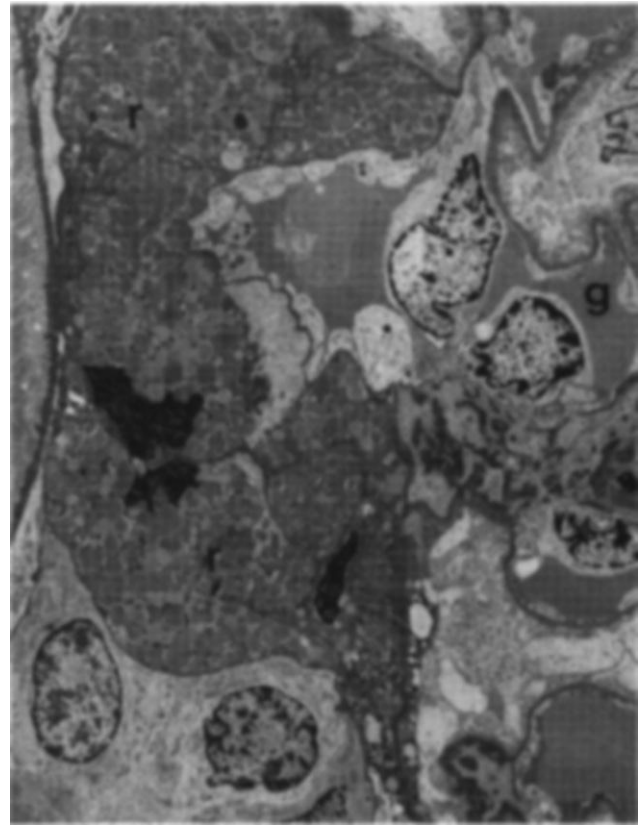


Fig. 5. Ultrastructural appearance of hilar arteriole entering glomerulus (g) with diffuse accumulation of membrane-bound renin granules (r) in arteriolar smooth muscle cells. 2400 \times .

smooth muscle cells present in the histologic associated plane of section, with diffuse eosinophilic granular transformation of the cell cytoplasm (Fig. 1 B, C). No evidence of glomerular injury, endothelial cell damage, or extracellular matrix deposition was detectable at this time point, although there was mild cortical tubular dilatation.

By days 26 and 35 after initiation of cyclosporine treatment, the arteriolar changes were more widespread, involving the majority of all identifiable arterioles. In affected vessels, the lesions more often, although not uniformly, involved all of the smooth muscle cells rather than just single cells, resulting in a circumferential appearance of the lesion (Fig. 2). As affected smooth muscle cells became hypertrophied, the distinct granular character of the eosinophilic transformation at times became obscured. Occasionally, the hyaline proteinaceous deposits encountered in day 26 and day 35 specimens were localized between viable smooth muscle cells of the vessel media, as well as occurring as discrete nodules at the adventitial surface of the vessel media (Fig. 3). This was indistinguishable from the pattern of cyclosporine arteriolopathy as it occurs in humans (Fig. 3E). These lesions were also associated with focal vacuolization of vessel smooth muscle cells. In no case were subendothelial hyaline accumulations identified as a principal manifestation of arteriolopathy, and in no case was there evidence of inflammatory cell infiltration of vessel walls.

In normal animals, immunohistochemical stains for renin

showed prominent circumferential expression of renin by all the SMC comprising the glomerular hilar arterioles, without evidence of expression within more proximal muscular arteries (Fig. 4A). Immunohistochemical detection of renin in CsA treated animals showed both enhanced staining of the juxtaglomerular (JG) apparatus, as well as staining of glomerular hilar arterioles that was often similar to that seen in control animals. However, in day 35 rats, there was focal accentuation of arteriolar staining in areas appearing to correspond to hyaline deposition (Fig. 4B). This could not be reliably ascertained due to the obscuring of underlying vessel architectural detail by the intense staining observed with the renin antibody. Most significantly, in day 35 CsA treated animals, there was proximal extension of normal arteriolar staining for renin, including distal portions of interlobular arteries in some vessels. However, this was not a uniform finding within the CsA group.

Electron microscopy of day 35 CsA treated animals demonstrated focal but dramatic changes in arterioles compared to controls. Smooth muscle cells of arterioles demonstrating focal or diffuse hyaline transformation, as detected by histologic examination of screening plastic sections, were found to contain diffuse cytoplasmic accumulations of membrane bound granules with a morphologic appearance characteristic of renin granules. In some arterioles there was diffuse transformation of all the smooth muscle cells comprising the vessel wall by this process (Fig. 5); in

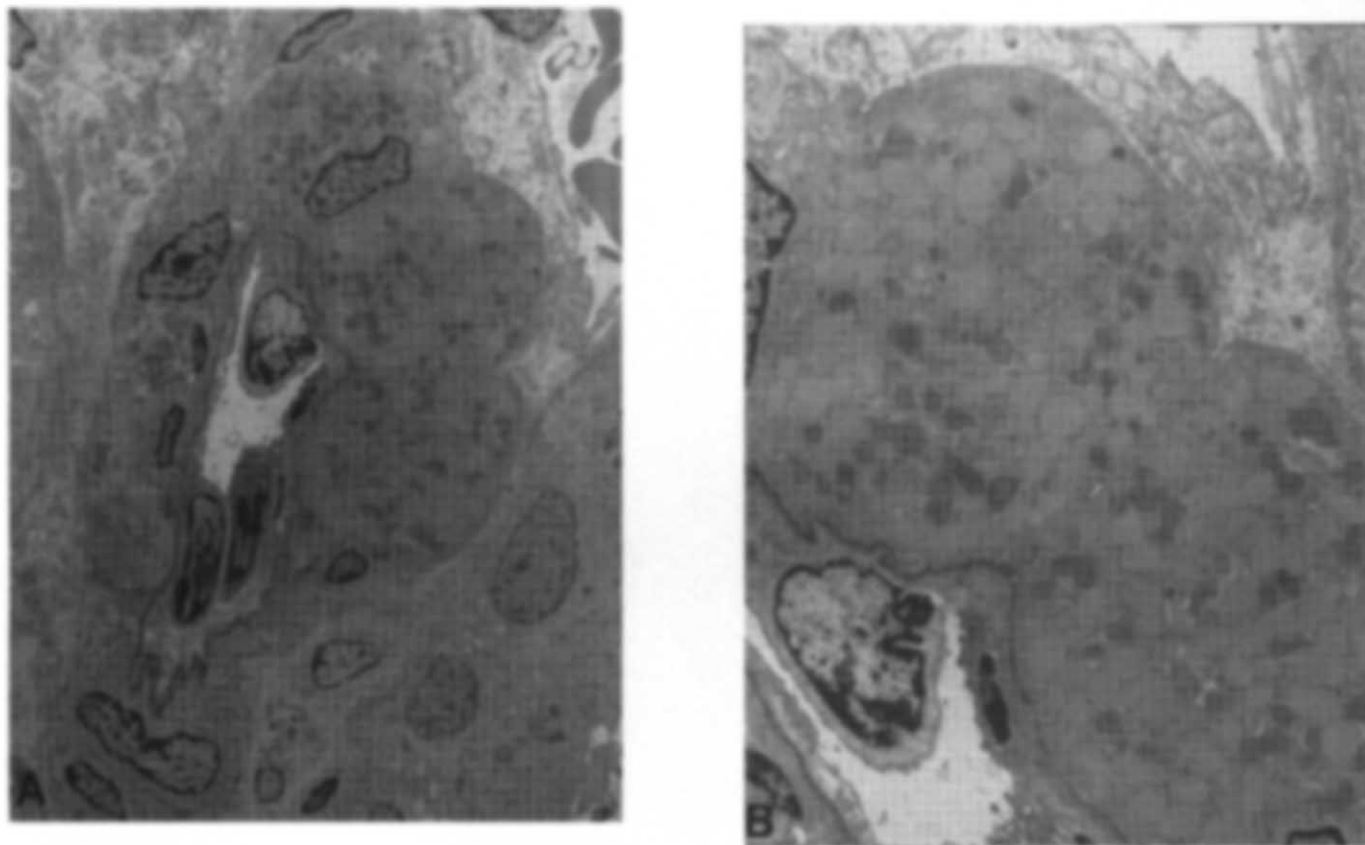


Fig. 6. **A.** Arteriole showing discrete involvement of some, but not all smooth muscle cells by a process of cell swelling and cytoplasmic accumulation of granules similar to those of Figure 5. 2270 \times . **B.** Higher magnification of vessel in A, also demonstrating cytoplasmic granules, and the absence of morphologic injury to endothelium. 4800 \times .

others the process involved only a subset of vascular smooth muscle cells (Fig. 6). These studies confirmed the discreteness of the injury to specific smooth muscle cells. Cells showing diffuse cytoplasmic transformation could be found adjacent to smooth muscle cells without any evidence of such injury. No ultrastructural abnormalities were discerned in glomeruli or arterial structures adjacent to affected arterioles. There appeared to be a morphologic transition between smooth muscle cells showing diffuse cytoplasmic accumulations of granules to cells showing lesser numbers of such granules dispersed in a finely granular, amorphous electron dense material similar to hyaline material ascribed to cellular and proteinaceous debris in the setting of human vascular injury (Fig. 7). No examples of hyaline-like deposits without some persistence of intracytoplasmic granules were detected within the time frame of this study.

Discussion

In humans, a number of systemic disease processes can result in arteriolar hyalinosis. These include hypertension, aging and diabetes. The microvascular manifestations occurring as a result of each of these injuries demonstrate considerable morphologic overlap, and are often indistinguishable. All are characterized by predominantly subendothelial collections of nondescript hyaline material, a material thought to be composed of insudated plasma proteins. CsA associated arteriolopathy (and perhaps FK 506

arteriolopathy as well) is distinguished from these other entities by the characteristic localization of hyaline deposits within the medial layers of smooth muscle cells and at the outer surface of affected vessels [27–29]. In this form of injury, subendothelial hyaline is not a characteristic feature. CsA arteriolopathy in humans also has a peculiar localization to afferent arterioles and terminal portions of interlobular arteries [27, 29, 30]. A model of cyclosporine arteriolopathy should replicate these morphologic findings as closely as possible and should be free of confounding physiologic parameters such as hypertension and hyperglycemia if at all possible.

In this report we document a model of chronic CsA nephropathy in normotensive rodents, with hyalinization of afferent arterioles that is strikingly similar to CsA-induced human arteriolopathy. The arteriolopathy appears to be widespread and progressive in the setting of continued CsA exposure. Perhaps most importantly, some morphologic features of this model closely resemble human CsA arteriolopathy by virtue of the distinct involvement of the muscular wall of the afferent arterioles as opposed to the nondescript, subendothelial accumulation of hyaline material that is nonspecifically found in other human arteriopathies as noted above, and furthermore, by the distinct anatomic localization to afferent arterioles and not the proximal portions of the renal arterial tree.

However, it must also be recognized that there may be some

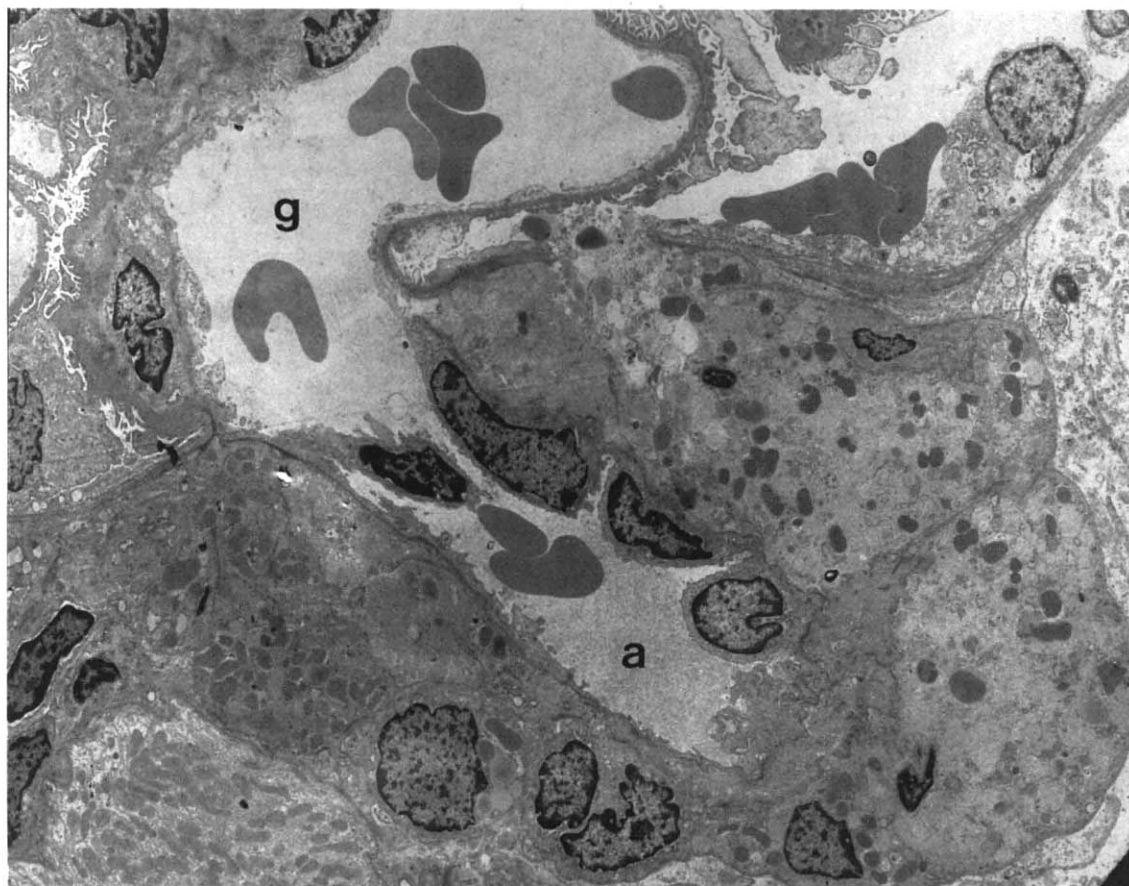


Fig. 7. Afferent arteriole (a) entering glomerulus (g). Arteriolar smooth muscle cells show diminished numbers of renin granules compared with vessels in Figures 5 and 6, and show some degeneration of organelle structures and cytoplasmic accumulation of ill defined, at times granular, pale material with some features of the hyaline material seen in human cyclosporine arteriolopathy. 2980 \times .

important differences between the rat model presented in this paper and human cyclosporine arteriolopathy. The demonstration of large accumulations of renin granules in the human lesion has not been reported, perhaps because the lesions identified in humans are typically well established and likely to represent a late stage in the morphological evolution of this injury. At such a juncture, there is extensive degenerative change within the injured smooth muscle cells, obscuring the features characteristic of developing injury as we have studied it in the rat. Furthermore, there is a potential discrepancy in relating cyclosporine arteriolopathy to increased arteriolar renin production in that plasma renin activity in humans treated with cyclosporine, unlike rats, is typically unchanged or even depressed compared to untreated controls [36]. However, this discrepancy may be more theoretical than real, since multiple intervening steps subsequent to renin synthesis and packaging in granules, which are not well characterized, but which include those regulating local renin secretion and activation, could have major effects on measured levels of renin activity.

Salt depletion appears to be a critical factor in the development of CsA arteriolopathy in the rat, as it is in other manifestations of experimental cyclosporine induced nephropathy [20, 21, 31]. This conclusion is based upon the observation that the arteriolopathy has not been identified to date in non-salt depleted models of

experimental cyclosporine injury in the rat. Salt depletion was originally employed to accentuate the "tubular glomerular feedback" loop [32] that contributes to increased renal vascular resistance via the renin-angiotensin system (RAS), which is based on the amount of chloride delivered to the macula densa of the distal tubule. The ensuing hypothesis predicts that salt-depletion would accelerate CsA induced disease in animals at least in part as a function of the resistance changes. Our study, in conjunction with the efforts of others who have not utilized salt depleted models, and who have not encountered noteworthy arteriolopathy, indicates CsA arteriolopathy also is accentuated in the salt-depleted rat model. This in turn implicates the renin-angiotensin system in the pathogenesis of this lesion, although other factors such as enhanced endothelin production or activity have clearly been implicated in this disease [33–35]. The morphologic correlation of smooth muscle "hyaline" injury and intracellular accumulation of renin granules detected by electron microscopy further identifies alterations in the intrarenal arteriolar renin system as an important component in the development of arteriolopathy. Finally, enhanced arteriolar accumulation of renin was detected immunocytochemically, a finding made by others as well [36], which also points to a role for local stimulation of renin production in the development of cyclosporine arteriolopathy.

With the model presented in this study, the hypothesis that

enhanced renin production and/or activity is essential to the development of CsA arteriopathy can be tested. For example, blockade of the RAS with the angiotensin-II receptor antagonist, Losartan [37], and the angiotensin converting enzyme-inhibitor, enalapril [38], reported to reduce interstitial fibrosis, can be examined as to whether or not they decrease the formation of the arteriopathy. Another test of validity of this model would be a more extended observational study to characterize the evolution of the arteriolar hyaline lesion into a more amorphous accumulation of granular hyaline material that is suggested by the findings in some day 35 experimental animals, and that is characteristic of established human CsA arteriopathy. A final approach would be immunohistochemical studies of human CsA arteriopathy in its various morphologic stages that might identify renin accumulation early in the development of this lesion. Each of these studies is currently under way.

CsA arteriopathy was at first thought to be an irreversible lesion, but now has shown to be reversible with stopping or lowering the dose of the drug [29, 30]. If validated, this model will allow a means to define therapeutic interventions that can contribute to amelioration of this form of injury.

In summary, the salt-depleted model of chronic cyclosporine nephropathy produces alterations of afferent arterioles which are similar to the lesion produced by CsA in humans. We conclude that this is a relevant model that may be used to study the long-term effects of cyclosporine nephrotoxicity.

Acknowledgments

Support for this study was provided by research grants from the US Public Health Service (DK34198, DK43422, DK02142, DK07659, HL42270, HL47151 and P30DK40566-04), a George M. O'Brien Kidney Center Grant (DK47659), and the Northwest Kidney Foundation. We thank Kelly Hudkins for technical assistance with electron microscopy.

Reprint requests to Charles E. Alpers, M.D., Department of Pathology, RC-72, University of Washington, Seattle, Washington 98195, USA.

References

- BOREL JF, FEUER C, GUBLER HU, STAHELIN H: The biological effects of cyclosporine A: A new antilymphocyte agent. *Agents Actions* 6:468-475, 1976
- MIHATSCH MJ, THIEL G, SPICHTIN HP, OBERHOLZER M, BRUNNER FP, HARDER F, OLIVIERI V, BREMER R, RYFFEL B, STÖCKLIN E, TORHORST J, GUDAT F, ZOLLINGER HU, LOERTSCHER R: Morphological findings in kidney transplants after treatment with cyclosporine. *Transplant Proc* (Suppl 1) 15:2821-2835, 1983
- OYER PE, STINSON EB, JAMIESON SW, HUNT SA, PERLROTH M, BILLINGHAM M, SHUMWAY NE: Cyclosporine in cardiac transplantation: A 2-1/2 year follow-up. *Transplant Proc* 15(Suppl 1):2546-2552, 1983
- MEYERS BD, ROSS J, NEWTON L, LUETSCHER J, PERLROTH M: Cyclosporine-associated chronic nephropathy. *N Engl J Med* 311:699-705, 1984
- GREENBERG A, EGEL JW, THOMPSON ME, HARDESTY RL, GRIFFITH BP, BAHNSON HT, BERNSTEIN RL, HASTILLO A, HESS ML, PUSCHETT JB: Early and late forms of cyclosporine nephrotoxicity: Studies in cardiac recipients. *Am J Kidney Dis* 9:12-22, 1987
- NIZZE H, MIHATSCH MJ, ZOLLINGER HU, BROCHERIOU C, GOKEL JM, HENRY K, SLOANE JP, STOVIN PG: Cyclosporine-associated nephropathy in patients with heart and bone marrow transplants. *Clin Nephrol* 30:248-260, 1988
- WHEATLEY HC, DATZMAN M, WILLIAMS JW, ILES DE, HATCH FE: Long-term effects of cyclosporine on renal function in liver transplant recipients. *Transplantation* 43:641-647, 1987
- KLINTMALM G, BOHMAN SO, SUNDELIN B, WILCZEK H: Interstitial fibrosis in renal allografts after 12 to 46 months of cyclosporine treatment: Beneficial effect of low doses in the early post-transplantation period. *Lancet* 2:950-954, 1984
- BERGSTRAND A, BOHMAN SO, FARNSWORTH A, GOKEL JM, KKRKAUSE PH, LANG W, MIHATSCH MJ, OPPEDAL B, SELL S, SIBLEY RK, THIRU S, VERANI R, WALLACE AC, SOLLINGER HU, RYFFEL B, THEIL G, WONIGEIT K: Renal histopathology in kidney transplant recipients immunosuppressed with cyclosporin A: results of an international workshop. *Clin Nephrol* 24:107-119, 1985
- RUIZ P, KOLBECK PC, SCROGGS MW, SANFILIPPO F: Associations between cyclosporine therapy and interstitial fibrosis in renal allograft biopsies. *Transplantation* 45:91-95, 1988
- SVENSON K, BOHMAN SO, HALLGREN R: Renal interstitial fibrosis and vascular changes. Occurrence in patients with autoimmune diseases treated with cyclosporine. *Arch Intern Med* 146:2007-2010, 1986
- PALESTINE AG, AUSTIN HA, BALOW JE, ANTONOVYCH TT, SABNIS SG, PREUSS HG, NUSSENBLATT RB: Renal histopathologic alterations in patients treated with cyclosporine for uveitis. *N Engl J Med* 314:1293-1298, 1986
- NAHMAN NS JR, COSIO FG, KOLKIN S, MENDELL JR, SHARMA HM: Cyclosporine nephrotoxicity without major organ transplantation. *Ann Intern Med* 106:400-402, 1987
- ANTONOVYCH TT, SABNIS SG, AUSTIN HA, PALESTINE AG, BALOW JE, NUSSENBLATT GB, HELFRICH GB, FOGEL ML, ALJANI MR: Cyclosporine A-induced arteriopathy. *Transplant Proc* 20(Suppl 3):951-958, 1988
- POWLES AV, COOK T, HULME B, BAKER BS, LEWIS HM, THOMAS E, VALDIMARSSON H, FRY L: Renal function and biopsy findings after 5 years' treatment with low-dose cyclosporin for psoriasis. *Brit J Derm* 128:159-165, 1993
- MIHATSCH MJ, THEIL G, RYFFEL B: Histopathology of cyclosporine nephrotoxicity. *Transplant Proc* 3:759-771, 1988
- RYFFEL B, SIEGL H, PETRIC R, MULLER AM, HANSEN R, MIHATSCH MJ: Nephrotoxicity cyclosporine in spontaneously hypertensive rats: Effects on blood pressure and vascular lesions. *Clin Nephrol* 25(Suppl 1):S193-S198, 1986
- FASEL J, KAISLING B, LUDWIG KS, RYFFEL B, MIHATSCH MJ: Light and electron microscopic changes in the kidney of Wistar rats following treatment with cyclosporine A. *Ultrastruct Pathol* 11:435-448, 1987
- THLIVERIS JA, YATSCOFF RW, LUKOWSKI MP, COPELAND KR, JEFFERY JR, MURPHY GF: Chronic ciclosporin nephrotoxicity: A rabbit model. *Nephron* 57:470-476, 1991
- ROSEN S, GREENFELD Z, BREZIS M: Chronic cyclosporine-induced nephropathy in the rat. *Transplantation* 49:445-452, 1990
- ELZINGA LW, ROSEN S, BENNETT WM: Dissociation of glomerular filtration rate from tubulointerstitial fibrosis in experimental chronic cyclosporine nephropathy: Role of sodium intake. *JASN* 4:214-221, 1993
- YOUNG B, BURDMANN E, JOHNSON R, ANDOH T, BENNETT W, COUSER W, ALPERS C: Arteriopathy and interstitial fibrosis (IF) in rats with chronic cyclosporine (CSA) nephrotoxicity. (abstract) *JASN* 4:762, 1993
- YOUNG BA, BURDMANN EA, JOHNSON RJ, ALPERS CE, GIACHELLI CM, ENG E, ANDOH T, BENNETT WM, COUSER WG: Cellular proliferation and macrophage influx precede interstitial fibrosis in cyclosporine nephrotoxicity. *Kidney Int* 48:000-000, 1995 (this issue)
- GALEN FX, DEVAUS C, ATLAS S, GUYENNE T, MENARD J, CORVOL P, SIMON D, CAZAUBON D, RICHLER P, BADOUILLE G, RICHARD JP, GROS P, PAU B: New monoclonal antibodies directed against human renin. *J Clin Invest* 74:723-735, 1984
- ENG E, VENIANT M, FLOEGE J, FINGERLE J, ALPERS CE, MENARD J, CLOZEL J, JOHNSON RJ: Renal proliferative and phenotypic changes in rats with two-kidney, one-clip Goldblatt hypertension. *Am J Hypertens* 7:177-185, 1994
- JOHNSON RJ, IIDA H, ALPERS CE, MAJESKY MW, SCHWARTZ SM, PRITZL P, GORDON K, GOWN AM: Expression of smooth muscle cell phenotype by rat mesangial cells in immune complex nephritis. *J Clin Invest* 87:847-858, 1991
- FEUTREN G, MIHATSCH MJ: Risk factors for cyclosporine-induced nephropathy in patients with autoimmune diseases. *N Engl J Med* 326:1654-1660, 1992

28. RANDHAWA PS, SHAPIRO R, JORDAN ML, STARZL TE, DEMETRIS AJ: The histopathological changes associated with allograft rejection and drug toxicity in renal transplants recipients maintained on FK506. *Am J Surg Pathol* 17:60-68, 1993
29. MOROZUMI K, THEIL G, ALBERT FW, BANFI G, GUDAT F, MIHATSCH MJ: Studies on morphological outcome of cyclosporine-associated arteriolopathy after discontinuation of cyclosporine in patients with renal allografts. *Clin Nephrol* 38:1-8, 1992
30. COLLINS BS, DAVIS CL, MARSH CL, McVICAR JP, PERKINS JD, ALPERS CE: Reversible cyclosporine arteriolopathy. *Transplantation* 54:732-765, 1992
31. BURDMANN EA, ANDOH TF, LINDSLEY J, MUNAR MY, ELZINGA LW, BENNETT WM: Experimental nephrotoxicity, hepatotoxicity and pharmacokinetics of cyclosporine G versus cyclosporine A. *Kidney Int* 45:684-691, 1994
32. GERKINS JF, BHAGWANDEEN SB, DOSEN PJ, SMITH AJ: The effect of salt intake on cyclosporine-induced impairment of renal function in rats. *Transplantation* 38:412-417, 1984
33. KON V, SUGIURA M, INAGAMI T, HARVIE BR, ICHIKAWA I, HOOVER RL: Role of endothelin in cyclosporine-induced glomerular dysfunction. *Kidney Int* 37:1487-1491, 1990
34. FOGO A, HELLINGS SE, INGAMI T, KON V: Endothelin receptor antagonism is protective in in vivo acute cyclosporine toxicity. *Kidney Int* 42:770-774, 1992
35. LANESE DM, CONGER JD: Effects of endothelin receptor antagonist on cyclosporine-induced vasoconstriction in isolated rat renal arterioles. *J Clin Invest* 91:2144-2149, 1993
36. MASON J, MÜLLER-SCHWEINITZER E, SUPONT M, CASELLAS D, MIHATSCH M, MOORE L, KASKEL F: Cyclosporine and the renin-angiotensin system. *Kidney Int* 39(Suppl 32):S28-S32, 1991
37. BURDMANN EA, ANDOH TF, NAST C, LINDSLEY J, EVAN A, CONNORS B, COFFMAN T, BENNETT WM: Dissociation between functional and structural changes in chronic cyclosporine (CSA) nephrotoxicity. (abstract) *JASN* 4:751, 1993
38. LAFAYELLE RA, MAYER G, MEYER TW: The effects of blood pressure reduction on cyclosporine nephrotoxicity in the rat. *JASN* 3:1892-1899, 1993