The Journal of Foot & Ankle Surgery

REVIEW

Surgical Approaches for Hallucal Sesamoid Excision

Richard Bouché, DPM, FACFAS,[1] and Eric Heit, DPM, ATC[2,3]

When encountering a patient with hallucal sesamoid pain, a specific diagnosis should be established. This is accomplished with a thorough history and physical examination, a comprehensive differential diagnosis, and timely diagnostic testing. Diagnosis will dictate treatment, which can vary significantly depending on the pathology involved. Conservative treatment is usually attempted initially followed by surgical treatment if conservative treatment fails and the patient is unable to function at his or her desired level of activity. Various surgical options for "sick" sesamoids[4] are available (Table 1). Sesamoidectomy has always been a prime consideration as one of the surgical procedures for alleviating symptoms of chronic sesamoid disorders though specific complications related to this surgery can occur and should be considered (Table 2). If the surgeon decides excision of one or both of the hallucal sesamoids is indicated, the surgical approach must be carefully considered, as controversy exists as to the best approach. This article reviews preferred surgical approaches for sesamoid excision based on blood supply to the hallucal sesamoids. Biomechanical implication on function of the first metatarsophalangeal joint after sesamoid extirpation is also reviewed.

Authors' Experience

For addressing "sick" sesamoid conditions, the senior author prefers total versus partial excision. Many of the complications associated with sesamoid excision are the result of a failure to preserve and balance the vital soft-tissue structures that envelop the sesamoids. This is probably due to the fact that traditional surgical approaches have not allowed adequate exposure to allow preservation of these structures. For example, in cases of tibial and fibular sesamoid excision without preservation of the flexor hallucis brevis tendon slips, a predictable complication of hallux hammertoe will result, prompting many surgeons to perform a prophylactic interphalangeal joint arthrodesis procedure. In the authors' experience, if the flexor hallucis brevis slips can be preserved at the time of sesamoidectomy, hallux hammertoe should not occur. In the case of isolated tibial or fibular sesamoidectomy, if the medial or lateral slip of the flexor hallucis brevis is preserved, respectively, complications will be unlikely. In cases of isolated tibial sesamoidectomy and low intermetatarsal angle ($\leq 8°$), hallux abductus is unlikely if medial augmentation and lateral release of the soft-tissue structures are performed. Medial augmentation includes plication of the medial capsule and abductor hallucis. Lateral release would include an adductor hallucis and extensor hallucis brevis tenotomy and, in some instances, a lateral capsulotomy.

Blood Supply of the Hallucal Sesamoids

When considering sesamoid excision, the blood supply to the sesamoids is of primary importance. The sesamoids are equally vascularized, possessing a multifocal and abundant blood supply. The blood supply enters the sesamoids at the proximal and distal nonarticular surfaces of the bones with the majority entering proximally (1). The proximal origin of these vessels is the medial plantar artery (MPA) and the plantar arch (PA) of the lateral plantar artery (LPA). The MPA and PA give rise to the plantar hallucal arteries, the medial proper plantar artery (MPPA) and the first plantar metatarsal artery (FPMA). The MPPA supplies the tibial sesamoid and the FPMA supplies the fibular sesamoid (2). Three distinct patterns of

From [1]Virginia Mason Sports Medicine, Seattle, WA and [2]Madigan Army Medical Center, Tacoma, WA. Address correspondence to: Richard Bouché, DPM, FACFAS, Virginia Mason Sports Medicine, 904 Seventh Avenue, Seattle, WA 98104.
[3] Resident, Madigan Army Medical Center.
[4] "Sick" sesamoids are defined as any chronic sesamoid condition unresponsive to conservative therapy and characterized by intractable pain and dysfunction.
The Journal of Foot & Ankle Surgery 1067-2516/02/4103-0192$4.00/0
Copyright © 2002 by the American College of Foot and Ankle Surgeons

TABLE 1 Surgical procedures for "sick sesamoids"

Partial sesamoid excision
Complete sesamoid excision
Sesamoid planing/shaving
Sesamoid fixation w/bone grafting
Combined tibial/fibular sesamoid excision w/IPJ fusion
Sesamoid implant
Dorsiflexory first metatarsal osteotomy
First MPJ arthrodesis w/ or w/o sesamoid excision
Peroneus longus tendon lengthening
Other

TABLE 2 Common complications of sesamoid excision

Procedure	Possible Complications
Tibial sesamoidectomy	Hallux abductus; hallux extensus; avascular necrosis of fibular sesamoid; flexor hallucis weakness; fibular sesamoid pathology; lesser metatarsalgia
Fibular sesamoidectomy	Hallux adductus; hallux extensus; avascular necrosis of tibial sesamoid; flexor hallucis weakness; tibial sesamoid pathology; lesser metatarsalgia
Tibial & fibular sesamoidectomy	Hallux hammertoe; hallux extensus; flexor hallucis weakness; lesser metatarsalgia

vascularization have been identified (Fig. 1) (2). Type A vascularization, the most common pattern with a 52% incidence, occurs when the plantar hallucal arteries take their origin equally from both the MPA and PA. Type B vascularization, with a 24% incidence, occurs when the plantar hallucal arteries arise from primarily the PA. Type C vascularization, also with a 24% incidence, occurs when the plantar hallucal arteries arise primarily from the MPA. These findings imply that during excision of the pathological sesamoid, if the procedure is not performed through

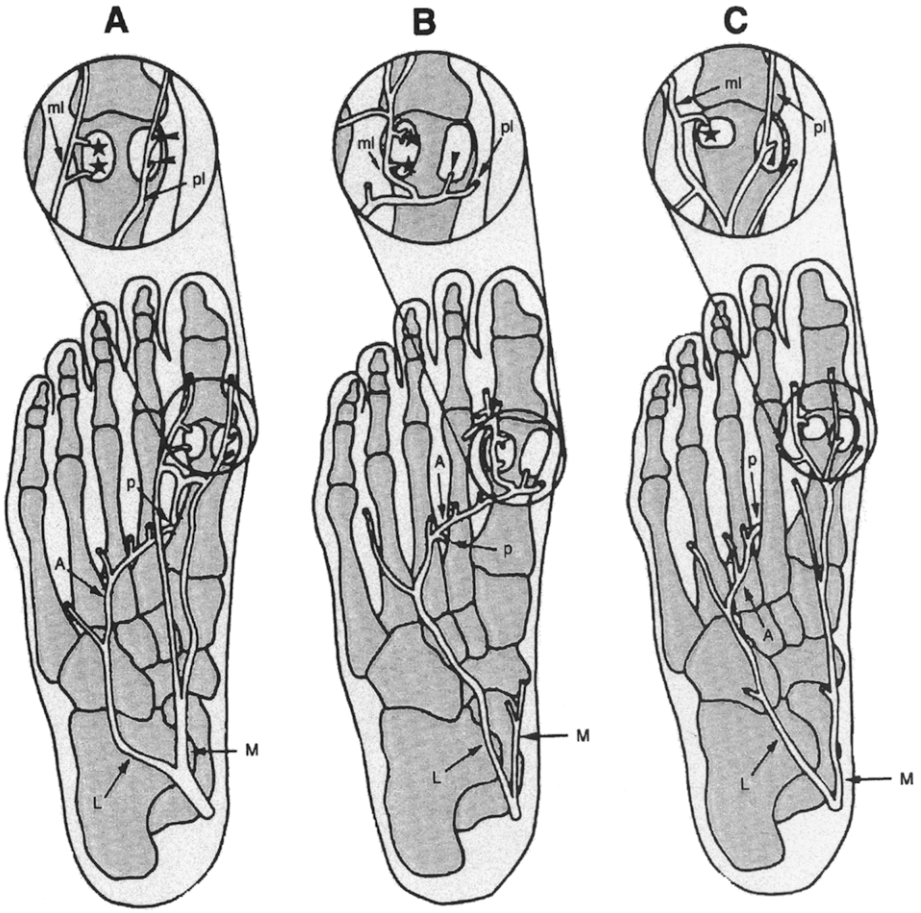

FIGURE 1 *A*, *B*, and *C*, Types of the plantar arteries of the hallux. *Encircled*: enlarged sketches of the plantar aspect of the first MTP joint with the sesamoid arteries entering the nonarticular surfaces of the sesamoids. *Arrowheads*, medial sesamoid arteries; *Stars*, lateral sesamoid arteries; M, medial plantar artery; A, plantar arch; L, lateral plantar artery; p, perforating branch of dorsalis pedis artery; ml, first plantar metatarsal artery; pl, proper plantar artery. (Reproduced, with permission, from Pretterklieber, M. L., Wanivenhaus, A. Foot Ankle 13(1):27–31, 1992.)

a well-vascularized soft-tissue envelope, then inadvertent disruption of the blood supply to the healthy sesamoid can occur.

Biomechanical Implications of Sesamoid Excision

Theoretically, complete excision of a sesamoid should weaken the flexor hallucis brevis (FHB) and could potentially weaken the flexor hallucis longus (FHL) as well. In two separate studies on partial versus total sesamoid excision and its relation to FHB and FHL moment arms, respectively, Aper et al. found only total excision of both sesamoids led to a decrease in the moment arm of the FHB (3) and total excision of the fibular, tibial, or both sesamoids significantly weakened the FHL (4). Partial excision of either sesamoid resulted in no significant decrease in moment arm of FHB or FHL (3, 4). The authors concluded that with singular total sesamoid excision with tendon repair, all the attachments of the FHB to the joint capsule and ligaments are still intact, thus preserving its function (3). The FHL has no capsular attachments and can move closer to its center of rotation after sesamoid excision, thus weakening the tendon (4). Isolated hemiresection of a sesamoid preserves the distance of the FHL to the center of rotation of the first metatarsophalangeal joint (MTPJ), resulting in no loss of moment arm (4). The authors make no conclusion about what, if any, deformity could occur over time, but hallux hammertoe is possible with loss of flexor hallucis brevis and weakening of the flexor hallucis longus. In summary, from an in vitro biomechanical perspective, FHL weakness can be expected with either a total single or double sesamoidectomy and FHB weakness can be expected with a double sesamoidectomy.

Suggested Surgical Approaches

Medial Incision for Tibial Sesamoidectomy

When isolated tibial sesamoidectomy is indicated, a medial-central longitudinal incision between the first dorsal and plantar digital proper nerves is recommended (Fig. 2). Advantages of this approach include the avoidance of a plantar incision, good exposure, limited potential for first MTPJ contracture, the ability to preserve the medial slip of the FHB, and avoidance of plantar digital nerves. This approach also gives the surgeon good exposure for any medial soft-tissue augmentation. The disadvantages of this incision are its proximity to the plantar-medial neurovascular bundle and possibility of a painful scar which may become irritated by shoe pressure.

After the incision has been performed, soft-tissue dissection is carried down to the abductor hallucis tendon/first MTPJ capsule level. A medial capsulotomy is then made at the level of the tibial sesamoid/first metatarsal head articulation. Exposure after capsulotomy will reveal the medial first metatarsal head condyle to be dorsal and the tibial sesamoid to be plantar. Excision of the tibial sesamoid begins medially and is best accomplished with a #67 blade, requiring meticulous dissection and attention to detail. Care should be taken to preserve the flexor hallucis brevis throughout the length of the incision. If the FHB tendon slip cannot be preserved or if significant laxity is evident, it should be repaired or imbricated, respectively. In the senior author's experience, the most difficult area of dissection is at the apex of the plantar aspect of the sesamoid where the tendon is usually thinnest. This area is where "buttonholing" of the FHB tendon often occurs. Once the sesamoid has been excised, integrity of the FHL tendon is assured by direct visualization. The procedure is completed with a layered closure.

Plantar Central Approach for Isolated Fibular or Combined Tibial and Fibular Sesamoidectomy

Plantar forefoot incisions are controversial because they involve a weightbearing surface. A plantar-central longitudinal incision between the sesamoids is recommended for excision of the fibular, or for both sesamoids (Fig. 3). The advantages of this incision are easier access to the sesamoids, direct visualization of the FHL tendon, and avoidance of the neurovascular bundle. Disadvantages include the possibility of a hypertrophic scar, the need for postoperative nonweightbearing for up to 4 weeks, and violation of the plantar fat pad. The senior author has found that as long as the incision is not perpendicular to the plantar MTPJ crease as it extends distally, a painful hypertrophic scar is unlikely.

After establishing the incision, soft-tissue dissection is carried down to the level of the FHL tendon sheath. The sheath is then incised and the FHL tendon is exposed and retracted. A longitudinal linear capsulotomy is made directly over the intersesamoidal ligament, an area of absent vascularity (2). The involved sesamoids are exposed in an "open book" fashion and are meticulously excised. Care is taken to preserve the FHL and FHB tendon slips. Any defects in the FHB tendon are repaired and after inspection of the FHL tendon, a layered closure follows.

In a study of 124 plantar incisions in 89 patients, 85 patients were pleased with their results (5). Although none of the incisions were used for sesamoidectomy (most plantar incisions were used for interdigital neuroma excision or adductor hallucis release) Richardson et al. recommend a plantar incision when a dorsal approach will not provide adequate exposure (5). Although few in number, various complications were noted, including inability to wear dress or high-heeled shoes,

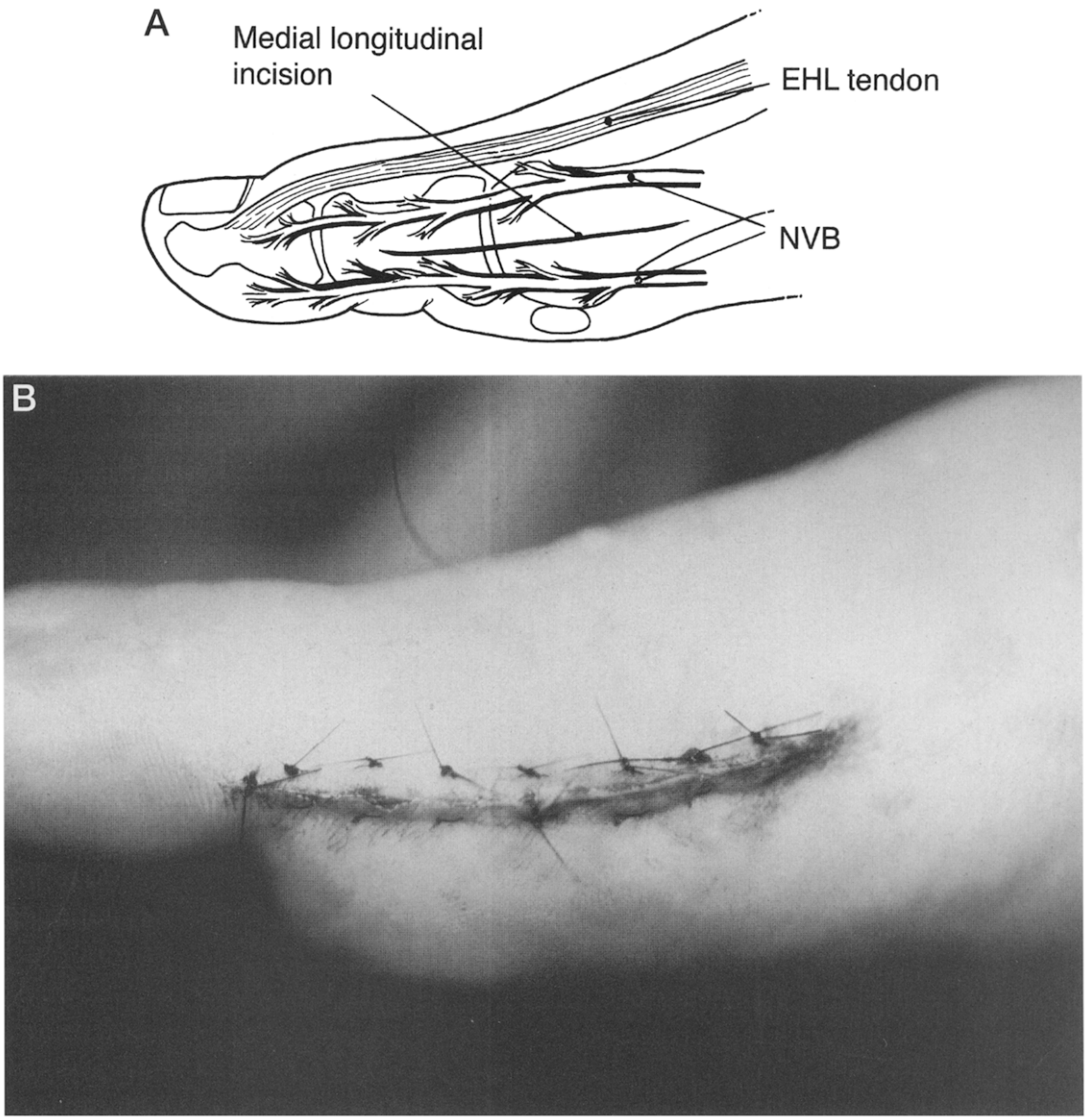

FIGURE 2 *A* and *B*, The medial-central longitudinal incision for tibial sesamoidectomy.

symptomatic plantar keratosis requiring excision, delayed wound healing, asymptomatic incisional keratosis, mild intermittent incisional tenderness, wound dehiscence, and hypertrophic scar formation.

Conclusion

Although sesamoid pathology is common, treatment and appropriate surgical approach remain enigmatic because of small patient samples, anecdotal evidence, and a lack of consistent terminology. There is much disagreement as to the correct conservative and surgical management of chronic sesamoid pathology. Surgical procedures and possible complications of these procedures, including biomechanical imbalances created by sesamoidectomy, continue to be a point of much controversy and need to be considered preoperatively. A comprehensive, prospective study on the effects of sesamoidectomy with evidence-based subjective and objective outcomes is needed.

Based on the vascular study by Pretterkleiber and Wanivenhaus the authors recommend a medial-central longitudinal incision for tibial sesamoidectomy and plantar-central longitudinal incision (between the sesamoids) for isolated fibular or combined tibial and fibular sesamoidectomy (2). Other incisional approaches (i.e., dorsal, medial-plantar, and plantar-lateral incisions) may interrupt the sesamoidal blood supply (2). Repair of the flexor hallucis brevis tendon slip(s) (3–14) after sesamoid excision is highly recommended to limit the potential complications. The authors have found these "suggested approaches" to total sesamoidectomy

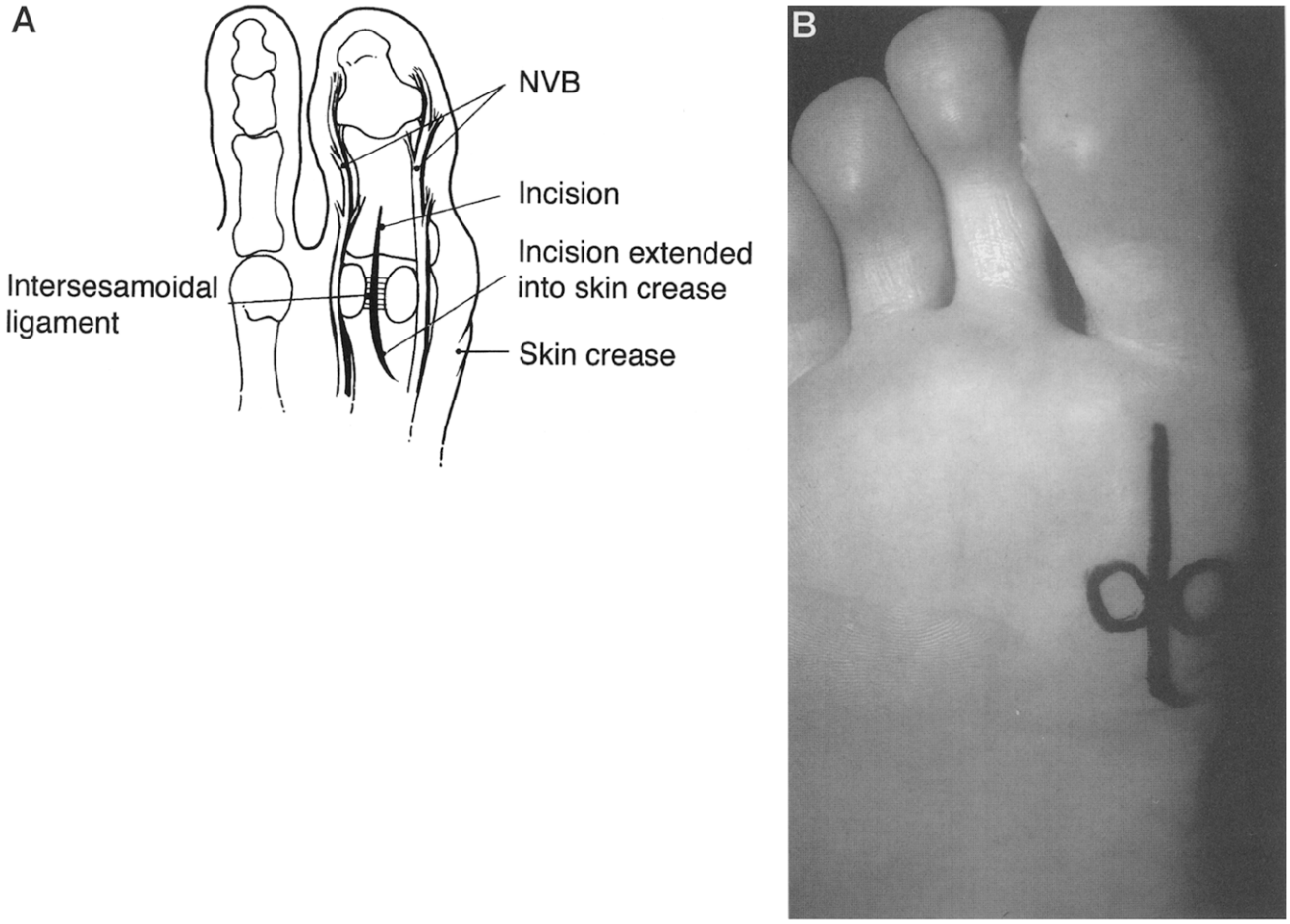

FIGURE 3 *A* and *B*, The plantar-central approach for isolated fibular or combined tibial and fibular sesamoidectomy.

to be reliable and reproducible with few postoperative complications encountered, though results need to be validated by further study and research.

References

1. Sobel, M., Hashimoto, J., Arnoczky, S. P., Bohne, W. H. O. The microvasculature of the sesamoid complex: its clinical significance. Foot Ankle 13(6):359–363, 1992.
2. Pretterklieber, M. L., Wanivenhaus, A. The arterial supply of the sesamoid bones of the hallux: the course and source of the nutrient arteries as an anatomical basis for surgical approaches to the great toe. Foot Ankle 13(1):27–31, 1992.
3. Aper, R. L., Saltzman, C. L., Brown, T. D. The effect of hallux sesamoid resection on the effective moment of the flexor hallucis brevis. Foot Ankle 15(9):462–470, 1994.
4. Aper, R. L., Saltzman, C. L., Brown, T. D. The effect of hallux sesamoid excision on the flexor hallucis longus moment arm. Clin. Orthop. 325:209–217, 1996.
5. Richardson, E. G., Brotzman, S. B., Graves, S. C. The plantar skin incision for procedures involving the forefoot. An evaluation of one hundred and fifty incisions in one hundred and fifteen patients. J. Bone Joint Surg. 75-A:726–731, 1993.
6. Bouché, R. T. Letter to the editor. J. Foot Ankle Surg. 36(5): 393–394, 1997.
7. Coughlin, M. J. Sesamoid pain: causes and surgical treatment. Instr. Course Lect. 39:23–35, 1990.
8. Goldman, F. Ipsilateral dual sesamoid injury: a case report. J. Am. Podiatr. Assoc. 74(4):187–191, 1984.
9. Leventen, E. O. Sesamoid disorders and treatment. An update. Clin. Orthop. 269:236–240, 1991.
10. Reinherz, R. P. Editorial. J. Foot Ankle Surg. 32(2):125, 1993.
11. Richardson, E. G. Hallucal sesamoid pain: causes and surgical treatment. J. Am. Acad. Orthop. Surg. 7(4):270–278, 1999.
12. Scranton, Jr., P. E., Rutkowski, R. Anatomic variations in the first ray: Part II. Disorders of the sesamoid. Clin. Orthop. 151:256–264, 1980.
13. Scranton, Jr., P. E. Pathologic anatomic variations in the sesamoids. Foot Ankle 1(6):321–326, 1981.
14. Van Hal, M. E., Keene, J. S., Lange, T. A., Clancy, Jr., W. G. Stress fractures of the great toe sesamoids. Am. J. Sports Med. 10(2):122–128, 1982.